

# Feasibility and long-term stability of surgically assisted rapid maxillary expansion with lateral osteotomy

Anu Anttila\*, Kaj Finne\*\*, Katri Keski-Nisula\*\*, Matti Somppi\*\*\*, Kari Panula\*\* and Timo Peltomäki\*,\*\*\*\*

\*Department of Oral Development and Orthodontics, Institute of Dentistry, University of Turku, \*\*Vaasa Central Hospital, \*\*\*Seinäjoki Central Hospital and \*\*\*\*Department of Oral Diseases, Turku University Central Hospital, Finland

**SUMMARY** Surgically assisted rapid maxillary expansion (SARME) has become a widely used and acceptable means to expand the maxilla in adolescents and adult patients. The method takes advantage of bone formation at the maxillary edges of the midline, while they are separated by an external force. The purpose of the present retrospective investigation was to evaluate the feasibility and long-term stability of maxillary expansion in patients in whom lateral pre-expansion osteotomy had been performed. The subjects were 20 patients (14 females, six males, mean age 30.6 years, range 16.2–44.2 years) whose malocclusions were treated solely or partly with SARME during 1988–1996. Two orthodontists carried out the post-orthodontic expansion treatment. The surgical technique followed a minimally invasive osteotomy on the lateral maxillary walls. Study models were obtained before surgery (T1), once expansion and the following orthodontic treatment were completed, before possible second-stage osteotomy (T2), and at long-term follow-up (T3). Using the study models, the width of the dental arch was measured with a digital sliding calliper. In addition, transverse occlusal relationships were examined at each time point.

The results indicated that (1) SARME is possible when the minimally invasive operation technique is used, (2) long-term stability of maxillary expansion following the present technique compares favourably with the widening and stability achieved with other, more invasive, osteotomies. With age, several possible uncertainties are introduced to affect the course of SARME adversely. Therefore, more extensive osteotomies can be recommended in older patients.

## Introduction

Surgically assisted rapid maxillary expansion (SARME) has become a widely used and acceptable means to expand the maxilla in adolescents and adult patients. The method takes advantage of bone formation at the maxillary edges of the midline, while they are separated by an external force. However, some controversies still exist concerning the indications, osteotomy technique, particularly in terms of the age of the patient, and long-term stability.

Primarily, SARME is indicated when the patient has isolated, considerable (more than 5 mm) transverse maxillary deficiency and is older than 15 years of age, and, therefore, not a good candidate for ordinary rapid maxillary expansion (Betts *et al.*, 1995; Bailey *et al.*, 1997; Silverstein and Quinn, 1997).

Several modifications to the surgical approach have been recommended and used. The rationale for choosing a particular osteotomy technique is based on the assumption of what structure(s) offers the most resistance to maxillary expansion. Those who consider the intermaxillary suture to be the essential resisting structure recommend first performing an osteotomy in the palate (MacIntosh, 1974; Timms and Vero, 1981).

Others regard the pterygomaxillary buttress, with its strong cortical bone, to be more important in preventing adequate expansion of the maxilla (Glassman *et al.*, 1984; Lehman *et al.*, 1984) and consequently perform an osteotomy only in the lateral areas. Many clinicians favour using combined osteotomies in the palate, anterior and lateral maxilla, and particularly at the pterygomaxillary buttress (Lines, 1975; Bell and Epker, 1976; Bays and Greco, 1992; Pogrel *et al.*, 1992; Betts *et al.*, 1995; Northway and Meade, 1997). It is evident that no consensus has been reached about the minimum osteotomy required to facilitate maxillary expansion, and that the question posed by Pogrel *et al.* (1992): 'What is the minimal procedure required to produce consistent and stable maxillary expansion in adults?' has not yet been answered.

Although the amount of maxillary expansion and its stability following SARME have been the topics of many investigations, the many different treatment regimes and follow-up periods make interpretation of the findings difficult. In general, it can be stated that expansion is greater in the anterior than in the posterior area, and relapse is 9–30 per cent in the canine area and 8–23 per cent in the molar area (Bays and Greco, 1992;

Mossaz *et al.*, 1992; Pogrel *et al.*, 1992; Racey, 1992; Strömberg and Holm, 1995; Northway and Meade, 1997; Berger *et al.*, 1998).

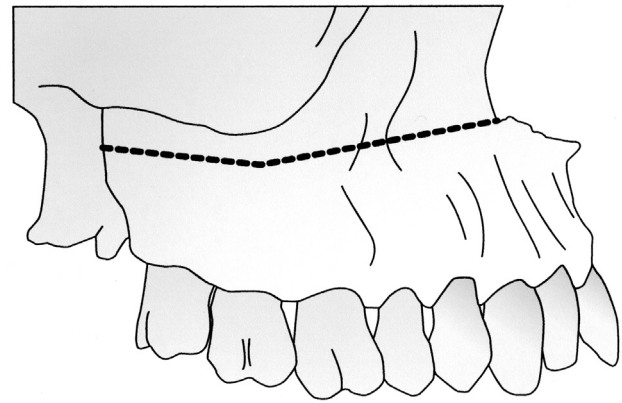
The purpose of the present retrospective study was to evaluate the feasibility and long-term stability of SARME in adult patients in whom only a lateral pre-expansion osteotomy had been performed. Schimming *et al.* (2000) concluded recently that this method would only be suitable for patients up to 30 years of age.

### Subjects and methods

The subjects were 20 patients who had undergone SARME at the Vaasa Central Hospital, Finland, during 1988–1996. The patients were mainly operated on by the same oral and maxillofacial surgeon (KF), and orthodontic treatment was carried out by two orthodontists (KK-N, MS). Of the 20 patients, 12 initially had a bilateral crossbite with or without anterior crossbite, six had a unilateral crossbite with or without anterior crossbite, and two had no crossbite but needed considerable maxillary expansion to facilitate mandibular advancement as the second-stage osteotomy.

All patients underwent a similar treatment regime. This consisted of placement of a rapid maxillary expander with bands on the first premolars and molars before surgery, and as close to the operation date as possible. In patients whose first premolars were missing, the anterior bands were placed on the second premolars. In 19 patients, a Hyrax-type expander was used with the expansion screw connected to a metal framework without an acrylic palatal cover. In one patient, a Haas-type expander with the acrylic palatal flanges incorporated into the appliance was used. The surgical technique followed the minimally invasive lateral osteotomy recommendation of Glassman *et al.* (1984) and Lehman *et al.* (1984). Briefly, under sedation and local anaesthesia, a bilateral ( $n = 18$ ) osteotomy from the rim of the piriform aperture to the pterygomaxillary suture was performed (Figure 1). Release of the pterygomaxillary suture was attempted with a curved osteotomy.

In order to verify that the osteotomy was initially adequate, the screw was opened three to six times in the operating theatre, resulting in a minor diastema opening or loosening of the contact between the upper first incisors. The patients were usually discharged from the hospital on the first post-operative day, when they were also requested to start opening the screw twice daily, i.e. 0.5 mm per day. Once the planned expansion with some over-expansion was achieved (mean 22 days, range 11–45 days), the appliance was kept in place, on average, for 6 months (range 3–11 months) to allow bone mineralization to occur. At this time, orthodontic treatment with fixed appliances was initiated to finalize the occlusion or to prepare the patient for a second-stage osteotomy ( $n = 15$ ).



**Figure 1** To facilitate surgically assisted rapid maxillary expansion (SARME), an osteotomy was performed bilaterally approximately 5 mm above the apices of the teeth from the rim of the piriform aperture to the pterygomaxillary suture.

The first pair of study models was taken before surgery (T1,  $n = 20$ , mean age 30.6 years, range 16.2–44.2 years, 10/20 patients were older than 30 years). The second models were taken once the expansion and the following orthodontic treatment were completed before a possible second osteotomy (T2,  $n = 20$ , mean T1–T2 interval 1.5 years, range 10 months–3.5 years). Long-term follow-up study models were available for 15 patients (T3,  $n = 15$ , mean T1–T3 interval 5.9 years, range 3.1–11.5 years). In addition, the stability of the expansion was examined in a subgroup of 12 subjects at least 2 years after removal of the orthodontic appliances (mean 4.7 years, range 2.8–9.3 years).

Using a digital sliding calliper, the maxillary transarch width was measured on the study models between the right and left canines, first and second premolars, and first and second molars, according to Moorrees (1959). In fact, two different width measurements were made: (1) from dental cusp to cusp and (2) from gingival margin to gingival margin of each tooth. For the first measurements, the crown tips of the canines, the palatal cusps of the premolars and the mesiopalatal cusps of the molars were lightly marked on the casts. For the second measurements, the most prominent point of the convex palatal crown surface of each tooth at the gingival level was marked. Once the measurements were performed, the points were immediately erased. Because of missing/extracted teeth, measurements could not be obtained from all the above sites in every subject. At each time point, occlusal relationships were also recorded on the study models. Information about the course of the treatment was obtained from the patients' files.

All the measurements were repeated after 2 weeks by the same investigator (AA), and the mean of the two measurements was used in the statistical analysis. Intra-examiner error between the two measurements was determined using a paired *t*-test and was found to

be statistically insignificant. A Wilcoxon signed rank test was used to assess the statistical significance of the changes in the width measurements between the different time points.

## Results

Measurements on the study models at the short-term examination (T2) showed that expansion of the maxillary arch was successful in all patients. There was, however, considerable interindividual variation in the expansion, reflecting the difference in the clinical need for expansion. The arch width increase was statistically significant for both occlusal and gingival measurements. The transarch width between the canines increased less than the other dimensions. The largest increase was recorded in the width between the second premolars and the first molars. Excluding canines, more expansion was found to have taken place in the occlusal than in the gingival dimensions (Table 1).

At the long-term examination (T3), the maxillary width was still significantly greater than before treatment (Table 1). However, some relapse between T2 and T3 measurements was noted for each tooth group.

Examination of the subgroup of 12 subjects more than 2 years after removal of the orthodontic appliances showed that the decrease in maxillary width was statistically significant in the measurements of the second premolars and the first and second molars. The relapse varied between 0.5 and 1.5 mm or, when expressed as relapse percentage, between 6 and 29 per cent (Table 2). It is also worth noting that for every measurement, excluding the canines, more relapse occurred in the occlusal compared with the gingival dimensions.

Despite statistical evidence that the relapse was significant, examination of the occlusion revealed that, in every case, maxillary expansion was maintained, and

that no constriction of the maxillary arch had taken place to the extent that the initial crossbite would have recurred.

Evaluation of the patients' files revealed that, in general, expansion proceeded uneventfully, although some complications had occurred during treatment. In three patients, the intermaxillary suture did not seem to open, rather the teeth tipped buccally and extruded. One of these patients had some initial bone loss because of previous periodontitis, and another was the oldest subject in the group (44.2 years). In one patient the roots of the premolars were exposed through the buccal alveolar bone. The patient with the Haas-type expander with acrylic palatal flanges had irritation in the palatal mucosa because of pressure exerted by the device. Two of the patients had a surgical complication: intra-operative bleeding and a post-operative wound healing problem, which were treated appropriately.

## Discussion

The present study indicates that SARME can be performed in adults when the minimally invasive operation technique on the lateral maxillary walls (Glassman *et al.*, 1984; Lehman *et al.*, 1984) is used. The long-term stability of expansion following the technique was found to compare favourably with the widening and stability achieved with other, more invasive, osteotomies reported in the literature (Bays and Greco, 1992; Mossaz *et al.*, 1992; Pogrel *et al.*, 1992; Racey, 1992; Strömberg and Holm, 1995; Northway and Meade, 1997; Berger *et al.*, 1998). Furthermore, it became evident that the technique was also suitable for over 30 year old subjects, as 50 per cent of the present patients were older than 30 years. This finding contrasts with those of Schimming *et al.* (2000).

Despite the feasibility of the technique in the present study population with an age range between 16.2 and

**Table 1** Increase in occlusal and gingival maxillary transarch width dimensions (mm) evaluated in the short (T2) and long (T3) term following surgically assisted rapid maxillary expansion (SARME) with lateral osteotomy.

Tooth	T2			T3		
	<i>n</i>	Mean	Range	<i>n</i>	Mean	Range
Canine, occlusal	18*	4.1	1.6–8.0	13*	3.7	2.1–6.5
Canine, gingival	18*	4.2	2.1–8.1	13*	3.8	2.1–6.1
First premolar, occlusal	15	6.8	3.2–10.1	10	6.0	1.6–8.4
First premolar, gingival	15	6.0	3.2–9.5	10	5.9	3.3–8.1
Second premolar, occlusal	18	7.2	2.3–12.0	13	5.7	1.7–10.9
Second premolar, gingival	18	6.6	2.5–11.6	13	5.6	2.3–10.0
First molar, occlusal	17	7.2	2.9–13.0	13	5.9	0.7–12.3
First molar, gingival	17	6.4	3.3–11.0	13	5.8	1.7–11.3
Second molar, occlusal	18	5.1	2.1–8.0	14	3.9	1.0–7.4
Second molar, gingival	18	4.9	1.9–7.3	14	4.0	2.2–5.9

\*Canine measurements of two patients were excluded because the canines were initially buccally malpositioned due to crowding, and the teeth were aligned to the dental arch during orthodontic treatment.

**Table 2** Relapse of occlusal and gingival maxillary transarch width dimensions following surgically assisted rapid maxillary expansion (SARME) with lateral osteotomy evaluated long-term in the subgroup of 12 subjects more than 2 years post-orthodontic debonding.

Tooth	<i>n</i>	Mean (mm)	Mean (%)
Canine, occlusal	10*	0.5	6
Canine, gingival	10*	0.5	8
First premolar, occlusal	9	0.7	12
First premolar, gingival	9	-0.2	-6
Second premolar, occlusal	11	1.5	22
Second premolar, gingival	11	0.8	14
First molar, occlusal	11	1.3	21
First molar, gingival	11	0.6	11
Second molar, occlusal	11	1.4	29
Second molar, gingival	11	1.1	21

A minus value indicates an increase in this measurement during the follow-up period.

\*Canine measurements of two patients were excluded because the canines were initially buccally malpositioned due to crowding, and the teeth were aligned to the dental arch during orthodontic treatment.

44.2 years, the age of the patient is a major factor to be taken into consideration when a SARME osteotomy is planned. Obliteration of the intermaxillary and other circummaxillary sutures gradually occurs with age, and this closure has an effect on the course of SARME. Whereas radiology has not proved to be a reliable method in assessing the state of the intermaxillary suture (Wehrbein and Yildizhan, 2001), the autopsy findings of Persson and Thilander (1977) are clinically relevant. It was found that there was great activity, yet large interindividual variation, in palatal sutural closure between 20 and 25 years of age. In most cases where SARME is attempted, the closure of the suture is not yet complete, and the small bony bridges between the maxillary halves can be broken with the heavy force created by the expansion device. Thus, the maxilla of 20–30 year old patients can easily be expanded with lateral osteotomies only, but with advancing age, osteotomies in the palate are also necessary. Persson and Thilander (1977) also reported that closure of the intermaxillary suture does not occur uniformly, and that obliteration of the intermaxillary suture starts posteriorly. Therefore, an additional osteotomy could be more advantageous in the posterior than in the anterior area between the incisors.

Age is also an important factor from another point of view. With advancing age, the likelihood of reduced bony support of the dentition increases. If prior bone loss has occurred, as seen in one of the patients in the present study, the force delivered by the expander is not transmitted to the intermaxillary and other skeletal structures, but rather the teeth will tip and/or extrude and less skeletal maxillary widening will occur.

In the present study, less expansion was noted between the canines than the other teeth. It can be speculated that the present technique, which does not include an osteotomy in the frontal area, may result in less expansion anteriorly. Interestingly, this finding is in agreement with the measurements of Handelman *et al.* (2000), who reported a smaller increase in the canine measurement when non-surgical rapid maxillary expansion was performed in adults. The finding that more relapse occurred in the occlusal than in the gingival measurements is probably due to unavoidable buccal tilting of the teeth, which are more prone to relapse than skeletal expansion, reflected by the gingival measurements (Moorrees, 1959).

## Conclusions

1. SARME is possible in adults when the minimally invasive operation technique on the lateral maxillary walls from the piriform aperture to the pterygo-maxillary suture is performed.
2. Long-term stability of maxillary expansion following the present technique compares favourably with the widening and stability achieved with other, more invasive, osteotomies reported in the literature.
3. A prerequisite for successful SARME is that the bone support of the teeth is not compromised.

With age, several possible uncertainties are introduced to adversely affect the course of SARME. Therefore, the question 'What is the minimal procedure required to produce consistent and stable maxillary expansion in adults' (Pogrel *et al.*, 1992) has to be related to the age of the patient. The proposal by Timms and Vero (1981) about 'age-related incremental surgical procedures' to facilitate SARME in adults can be corroborated.

## Address for correspondence

Timo Peltomäki  
Department of Oral Development and Orthodontics  
Institute of Dentistry, University of Turku  
Lemminkäisenkatu 2  
FIN-20520 Turku  
Finland

## References

- Bailey L J, White R P, Proffit W R, Turvey T A 1997 Segmental LeFort I osteotomy for management of transverse maxillary deficiency. *Journal of Oral and Maxillofacial Surgery* 55: 728–731
- Bays R A, Greco J M 1992 Surgically assisted rapid palatal expansion: an outpatient technique with long-term stability. *Journal of Oral and Maxillofacial Surgery* 50: 110–113
- Bell W H, Epker B N 1976 Surgical-orthodontic expansion of the maxilla. *American Journal of Orthodontics* 70: 517–528

- Berger J L, Pangrazio-Kulbersh V, Borgula T, Kaczynski R 1998 Stability of orthopedic and surgically assisted rapid palatal expansion over time. *American Journal of Orthodontics and Dentofacial Orthopedics* 114: 638–645
- Betts N J, Vanarsdall R L, Barber H D, Higgins-Barber K, Fonseca R J 1995 Diagnosis and treatment of transverse maxillary deficiency. *International Journal of Adult Orthodontics and Orthognathic Surgery* 10: 75–96
- Glassman A S, Nahigan S J, Medway J M, Aronowitz H I 1984 Conservative surgical orthodontic adult rapid maxillary expansion: sixteen cases. *American Journal of Orthodontics* 86: 207–213
- Handelman C S, Wang L, BeGole E A, Haas A J 2000 Nonsurgical rapid maxillary expansion in adults: report of 47 cases using the Haas expander. *Angle Orthodontist* 70: 129–144
- Lehman J A, Haas A J, Haas D G 1984 Surgical orthodontic correction of transverse maxillary deficiency: a simplified approach. *Plastic and Reconstructive Surgery* 73: 62–66
- Lines P A 1975 Adult rapid maxillary expansion with corticotomy. *American Journal of Orthodontics* 67: 44–56
- MacIntosh R B 1974 Total mandibular alveolar osteotomy. *Journal of Maxillofacial Surgery* 2: 210–218
- Moorrees C F A 1959 The dentition of the growing child. Harvard University Press, Cambridge
- Mossaz C F, Byloff F K, Richter M 1992 Unilateral and bilateral corticotomies for correction of maxillary transverse discrepancies. *European Journal of Orthodontics* 14: 110–116
- Northway W M, Meade Jr J B 1997 Surgically assisted rapid maxillary expansion: a comparison of technique, response, and stability. *Angle Orthodontist* 67: 309–320
- Persson M, Thilander B 1977 Palatal suture closure in man from age 15 to 35 years of age. *American Journal of Orthodontics* 72: 42–52
- Pogrel M A, Kaban L B, Vargervik K, Baumrind S 1992 Surgically assisted rapid maxillary expansion in adults. *International Journal of Adult Orthodontics and Orthognathic Surgery* 7: 37–41
- Racey G L 1992 Surgically assisted rapid palatal expansion: an outpatient technique with long-term stability. *Journal of Oral and Maxillofacial Surgery* 50: 114–115 (Discussion)
- Schimming R, Feller K-U, Herzmann K, Eckelt U 2000 Surgical and orthodontic rapid palatal expansion in adults using Glassman's technique: retrospective study. *British Journal of Oral and Maxillofacial Surgery* 38: 66–69
- Silverstein K, Quinn P D 1997 Surgically-assisted rapid palatal expansion for management of transverse maxillary deficiency. *Journal of Oral and Maxillofacial Surgery* 55: 725–727
- Strömberg C, Holm J 1995 Surgically assisted rapid maxillary expansion in adults: a retrospective long-term follow-up study. *Journal of Craniomaxillofacial Surgery* 23: 222–227
- Timms D J, Vero D 1981 The relationship of rapid maxillary expansion to surgery with special reference to midpalatal synostosis. *British Journal of Oral Surgery* 19: 180–196
- Wehrbein H, Yildizhan F 2001 The mid-palatal suture in young adults. A radiological–histological investigation. *European Journal of Orthodontics* 23: 105–114

